



REVIEW: ENDOSCOPY

Why you do or do not need thoracoscopy

J.P. Janssen

ABSTRACT: Thoracoscopy is an old but still very valuable technique for the evaluation of pleural pathology and, especially for the further investigation of the aetiology of pleural fluid. It remains of great importance, since it is able to not only provide an exact diagnosis, but also can have therapeutic potential. In this review, the differential diagnostic aspects of transudate *versus* exudate are further elaborated, and the role of thoracoscopy is compared to closed pleural biopsy and image guided biopsy.

KEYWORDS: Medical, pleuroscopy, thoracoscopy

Thoracoscopy is not new; this year we will celebrate the Centennial of Thoracoscopy, as the first thoracoscopic procedure was performed by the Swedish internist H.C. Jacobaeus in 1910. Today, thoracoscopy is still a valuable tool in the diagnosis and treatment of pleural diseases. In this review, we will discuss the diagnostic and therapeutic aspects of thoracoscopy in patients with pleural effusion. Thoracoscopy has a place in the diagnosis and treatment of other diseases, such as pneumothorax, palmary hyperhidrosis and empyema. These diseases will not be discussed here.

DIAGNOSTIC ASPECTS OF THORACOSCOPY

The flow chart of the work-up of pleural effusion is presented in figure 1. Thoracocentesis is the first procedure to be performed in a pleural effusion of >1 cm diameter in lateral decubitus position [1]. The most important step in narrowing the differential diagnosis is to distinguish a transudate from an exudate. To do this, Light's criteria (ratio of pleural fluid/serum protein >0.5, ratio of pleural fluid/serum lactate dehydrogenase (LDH) >0.6 or pleural fluid LDH more than two-thirds of the upper limit of normal serum value) are still appropriate [1].

If the protein level is >35 g·L⁻¹, the effusion is most likely an exudate [2]. In borderline exudates (protein level >25 but <35 g·L⁻¹) Light's criteria may misclassify transudates in up to 20% of cases, especially in patients with congestive heart failure who have been on diuretics. To discriminate true transudates from pseudo-exudates, measurement of the pleural protein gradient or the pleural fluid albumin gradient can be applied: if serum protein level minus pleural protein level is >3.1 g·dL⁻¹, or

serum albumin level minus pleural albumin level is >1.2 g·dL⁻¹, it is a transudate [1]. In recent studies, measurement of pro-B-type natriuretic peptide (pro-BNP) in pleural fluid and serum appeared to be promising in the diagnosis of transudates in patients with chronic heart failure. In case of possible misclassification by the use of Light's criteria, measurement of pro-BNP level may appear to be a better tool to differentiate a transudate from a pseudo-exudate [3–6].

In the case of an exudate, and benign or non-conclusive cytology, infection, pulmonary embolism and abdominal disease should be considered. If these diseases have been ruled out or are very unlikely, the exudate is caused by malignant disease, tuberculosis or the exudate is idiopathic.

In the past, it has been stated that a malignant pleural effusion can also occur as a transudate [7]. This is most likely due to imperfect application of the diagnostic rules, or comorbid conditions like hypoalbuminaemia, cirrhosis with ascites or chronic heart failure.

ANALYSIS OF AN EXUDATE

In the case of a proven exudate with non-conclusive cytology after (repeated) thoracocentesis, an additional procedure to obtain pleural histology tissue is the next step. This can be done with a minimal invasive procedure in four ways: closed pleural biopsy (CPB; Abrams biopsy), thoracoscopy, ultrasound (US)-guided biopsy, and computed tomography (CT)-guided biopsy. A comparison of these techniques is summarised in table 1.

CPB (ABRAMS BIOPSY)

CPB is an old technique. In patients with pleural effusion, a blind biopsy of the parietal pleura can

CORRESPONDENCE

J.P. Janssen
Dept of Pulmonary Diseases B01
Canisius Wilhelmina Hospital
Post box 9015
6500 GS Nijmegen
The Netherlands
E-mail: j.janssen@cwz.nl

Received:

May 25 2010

Accepted:

May 26 2010

PROVENANCE

Publication of this peer-reviewed article was supported by GlaxoSmithKline, Belgium (principal sponsor, *European Respiratory Review* issue 117).

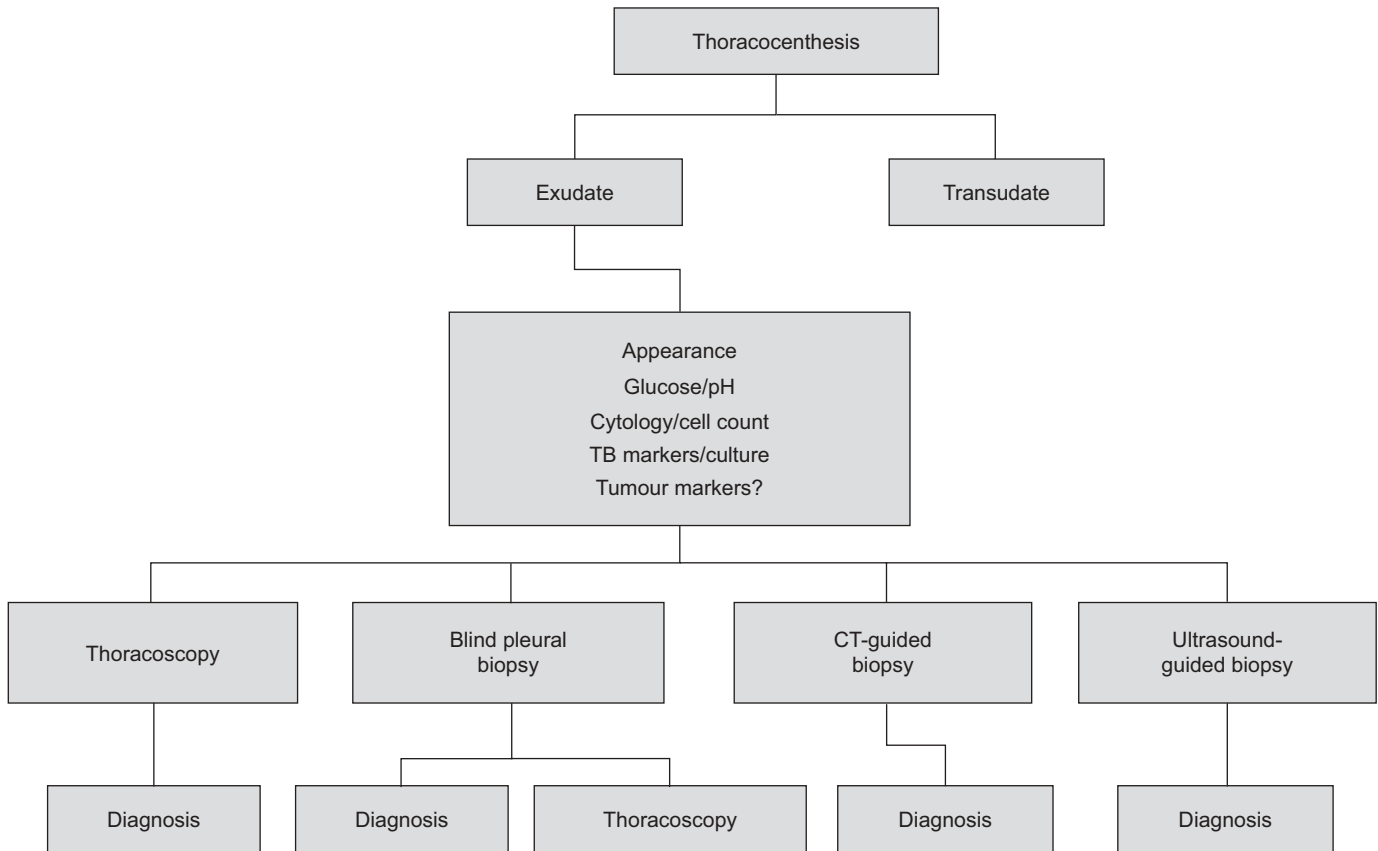


FIGURE 1. The diagnostic work-up of pleural effusion. CT: computed tomography.

be obtained. In malignant pleural disease, the additional diagnostic yield of CPB after thoracocentesis is limited to 7% [8].

The diagnostic yield of CPB is better in areas with high incidence of tuberculosis (TB), as has been demonstrated by DIACON *et al.* [9]. In their study, the diagnostic yield of the combination of TB culture and histology reached 79%, with a

sensitivity of 93%, if combined with serum adenosine deaminase level and lymphocytosis of the pleural fluid (lymphocytes/neutrophils >0.75). In a prospective study in the UK, MASKELL *et al.* [10] compared CPB with CT-guided pleural biopsy. The results for the CT group were: sensitivity 87%, specificity 100% and negative predictive value 80%. In the CPB group the results were: sensitivity 47%, specificity 100% and negative predictive value 44%.

TABLE 1 Comparison of techniques to obtain pleural biopsy

	Closed pleural biopsy	Thoracoscopy	Computed tomography-guided biopsy	Ultrasound-guided biopsy
Sensitivity	40–45% [#]	90–95%	87%	85%
Specificity	100%	100%	100%	100%
Performed by	Pulmonologist	Pulmonologist	Radiologist	Radiologist or pulmonologist
Advantages	Outpatient procedure Cheap	Diagnostic procedure can be combined with therapeutic intervention in one session	Small lesions and difficult locations can be reached	Widely available Real-time image No radiation exposure
Disadvantages	Blind procedure Low diagnostic yield [#]	In-patient procedure	Radiation exposure Prior contrast computed tomography to localise area of pleural disease	Prior contrast computed tomography to localise area of pleural disease

[#]: diagnostic yield is higher in areas with endemic tuberculosis.

TABLE 2 The diagnostic yield of thoracoscopy

First author [ref.]	Year	Cases n	Diagnostic yield %	NSP	False negative cases of NSP during follow-up	Follow-up period
BOUTIN [12]	1981	215	97	40 (19)	19 (9)	1 yr
LODDENKEMPER [13]	1981	250	98	23 (9)		NS
PAGE [14]	1989	125	91.5	15 (12)	22 (18)	NS
MENZIES [15]	1991	102	93	22 (21)		>1 yr
HUCKER [16]	1991	102	80	21 (20)	NS	NS
KENDALL [17]	1992	48	83	24 (50)	6 (25)	>1 yr
OHRI [18]	1992	56	85.7	7 (12.5)	1 (2)	NS
FERRER [19]	1996	394	86.5	53 (13.5)	2 (5)	>1 yr
HANSEN [20]	1998	147	90.4	45 (31)	12 (8)	2 yrs
BLANC [21]	2002	168	93.3	57 (38.2)		>1 yr

Data are presented as n (%), unless otherwise stated. NSP: nonspecific pleuritis; NS: not stated.

In conclusion, CPB should no longer be used in a setting where image-guided pleural biopsies can be obtained. Use of CPB is only indicated in areas with high incidence of TB and limited medical resources [9].

CT- VERSUS US-GUIDED PLEURAL BIOPSY

There are no comparative studies of the diagnostic yield of CT- and US-guided biopsy; the diagnostic sensitivity of both techniques is high (>83%) [11]. The characteristics of each procedure are summarised in table 1.

THORACOSCOPY VERSUS IMAGE-GUIDED PROCEDURES

The diagnostic yield of thoracoscopy is high; it is reported to be >90% in the majority of studies (table 2). Although it is a more invasive procedure compared with image-guided pleural biopsy, the big advantage of thoracoscopy is the possibility to perform a therapeutic intervention in the same session as the diagnostic biopsy of the pleura.

The possible therapeutic procedures during thoracoscopy are: 1) removal of (septated) pleural effusions; 2) talc poudrage (under visual control if preferred); and 3) drain positioning under visual control.

Thoracoscopy is the preferred procedure if no clear target lesion is visible on the CT scan, and in patients with large or recurrent effusions, in whom drainage and pleurodesis is indicated. Image-guided pleural biopsy may be the procedure

of choice in elderly, unfit patients with small pleural effusions. The diagnostic work-up of a pleural effusion is summarised in figure 1.

HOW TO DEAL WITH UNDIAGNOSED PLEURAL EFFUSION

After a complete work-up of pleural effusion including thoracoscopy, a specific diagnosis may not be available in a considerable amount of cases (table 2).

This condition is described as “idiopathic pleuritis”, “unspecific pleuritis”, “nonspecific pleuritis” or “pleuritis with indeterminate cause”. This specific problem has been retrospectively addressed by four studies, three of which included thoracoscopy in the work-up, and one thoracotomy [19, 22–24]. The results of these studies are summarised in table 3.

In our study of 208 patients with a nonspecific pleuritis after thoracoscopy, 85% followed a benign course during follow-up [23]. A “wait and see” approach is therefore justified in the majority of these patients. An extended video-assisted thoracoscopic surgery procedure is indicated in case of a difficult thoracoscopy with adhesions and layers of fibrin, especially if there is a clinical suspicion of mesothelioma. Otherwise, the patients should be monitored with regular chest radiography. In case of a persistent or increasing pleural effusion, thoracentesis should be repeated. If the analysis of the pleural fluid is showing a lymphocytosis or increased LDH, the thoracoscopy should be repeated [23].

TABLE 3 Long-term follow-up of nonspecific pleuritis (NSP) after a diagnostic thoracoscopy or thoracotomy; eventually, malignant pleuritis was found in 5–25%

First author [ref.]	Procedure	Patients with NSP n	Eventual outcome
RYAN [22]	Thoracotomy	51	Malignant pleuritis 13 (25.5%)
FERRER [19]	Thoracoscopy	40	Malignant pleuritis 2 (5%)
JANSSEN [23]	Thoracoscopy	208	Malignant pleuritis 31 (15%)
VENEKAMP [24]	Thoracoscopy	68	Malignant pleuritis 5 (8.3%)

CONCLUSIONS

Thoracoscopy is an old, safe and simple procedure. Any pulmonologist who deals with pleural disease nowadays should be able to perform thoracoscopy. The diagnostic yield of pleural effusions under CT or US guidance is only slightly inferior to thoracoscopy (85% versus >90%). Thoracoscopy is the preferred procedure if no clear target lesion is visible on the CT scan. Also, thoracoscopy is preferred if removal of pleural effusion and/or pleurodesis is indicated, because during thoracoscopy the diagnostic and therapeutic procedure can be performed in the same session.

STATEMENT OF INTEREST

None declared.

REFERENCES

- 1 Light RW. Approach to the patient. In: Light RW. Pleural Diseases. 5th Edn. Philadelphia, Lippincott Williams and Wilkins, 2007; pp. 109–119.
- 2 Maskell NA, Butland RJA. BTS guidelines for the investigation of a unilateral pleural effusion in adults. *Thorax* 2003; 58: ii8–ii17.
- 3 Porcel JM, Chorda J, Cao G, et al. Comparing serum and pleural fluid pro-brain natriuretic peptide (NT-proBNP) levels with pleural-to-serum albumin gradient for the identification of cardiac effusions misclassified by Light's criteria. *Respirology* 2007; 12: 654–659.
- 4 Kolditz M, Halank M, Schiemanck CS, et al. High diagnostic accuracy of NT-proBNP for cardiac origin of pleural effusions. *Eur Respir J* 2006; 28: 144–150.
- 5 Han C H, Choi J E, Chung J H. Clinical utility of pleural fluid NT-proBNP in patients with pleural effusions. *Intern Med* 2008; 47: 1669–1674.
- 6 Seyhan EC, Altin S, Cetinkaya E, et al. The importance of pleural fluid and serum NT-proBNP levels in differentiating pleural effusion due to heart failure from other causes of effusion. *Intern Med* 2009; 48: 287–293.
- 7 Ashchi M, Golish J, Eng P, et al. Transudative malignant pleural effusions; prevalence and mechanisms. *South Med J* 1998; 91: 23–32.
- 8 Prakash UBS. Comparison of needle biopsy with cytologic analysis for the evaluation of pleural effusion: analysis of 414 cases. *Mayo Clin Proc* 1985; 60: 158–164.
- 9 Diacon AH, Van de Wal BW, Wyser C, et al. Diagnostic tools in tuberculous pleurisy: a direct comparative study. *Eur Respir J* 2003; 22: 589–591.
- 10 Maskell NA, Gleeson FV, Davies RJ. Standard pleural biopsy versus CT-guided cutting-needle biopsy for diagnosis of malignant disease in pleural effusions: a randomised controlled trial. *Lancet* 2003; 361: 1326–1330.
- 11 Rahman NM, Gleeson FV. Image-guided pleural biopsy. *Curr Opin Pulm Med* 2008; 14: 331–336.
- 12 Boutin C, Vierrat JR, Cargnino P, et al. Thoracoscopy in malignant pleural effusions. *Am Rev Respir Dis* 1981; 124: 588–592.
- 13 Loddenkemper R. Thoracoscopy: results in non cancerous and idiopathic pleural effusions. *Poumon Coeur* 1981; 37: 261–264.
- 14 Page RD, Jeffrey RR, Donnelly RJ. Thoracoscopy: a review of 121 consecutive surgical procedures. *Ann Thorac Surg* 1989; 48: 66–68.
- 15 Menzies R, Charbonneau M. Thoracoscopy for the diagnosis of pleural disease. *Ann Intern Med* 1991; 114: 271–276.
- 16 Hucker J, Bhatnagar NK, Al-Jilaihawi AN, et al. Thoracoscopy in the diagnosis and management of recurrent pleural effusions. *Ann Thorac Surg* 1991; 52: 1145–1147.
- 17 Kendall SWH, Bryan AJ, Large SR, et al. Pleural effusions: is thoracoscopy a reliable investigation? A retrospective review. *Respir Med* 1992; 86: 437–440.
- 18 Ohri SK, Oswal SK, Townsend ER, et al. Early and late outcome after diagnostic thoracoscopy and talc pleurodesis. *Ann Thorac Surg* 1992; 53: 1038–1041.
- 19 Ferrer JS, Munoz XG, Orriols RM, et al. Evolution of idiopathic effusion. A prospective long term follow-up study. *Chest* 1996; 109: 1508–1513.
- 20 Hansen M, Faurschou P, Clementsen P. Medical thoracoscopy, results and complications in 146 patients: a retrospective study. *Respir Med* 1998; 92: 228–232.
- 21 Blanc FX, Atassi K, Bignon J, et al. Diagnostic value of medical thoracoscopy in pleural disease. A 6-year retrospective study. *Chest* 2002; 121: 1677–1683.
- 22 Ryan CJ, Rodgers RF, Unni KK, et al. The outcome of patients with pleural effusion of indeterminate cause at thoracotomy. *Mayo Clin Proc* 1981; 56: 145–149.
- 23 Janssen JP, Ramlal S, Mravunac M. The long-term follow-up of exudative pleural effusion after nondiagnostic thoracoscopy. *J Bronchol* 2004; 11: 169–174.
- 24 Venekamp LN, Velkeniers B, Noppen M. Does “idiopathic pleuritis” exist? Natural history of non-specific pleuritis diagnosed after thoracoscopy. *Respiration* 2005; 72: 74–78.